



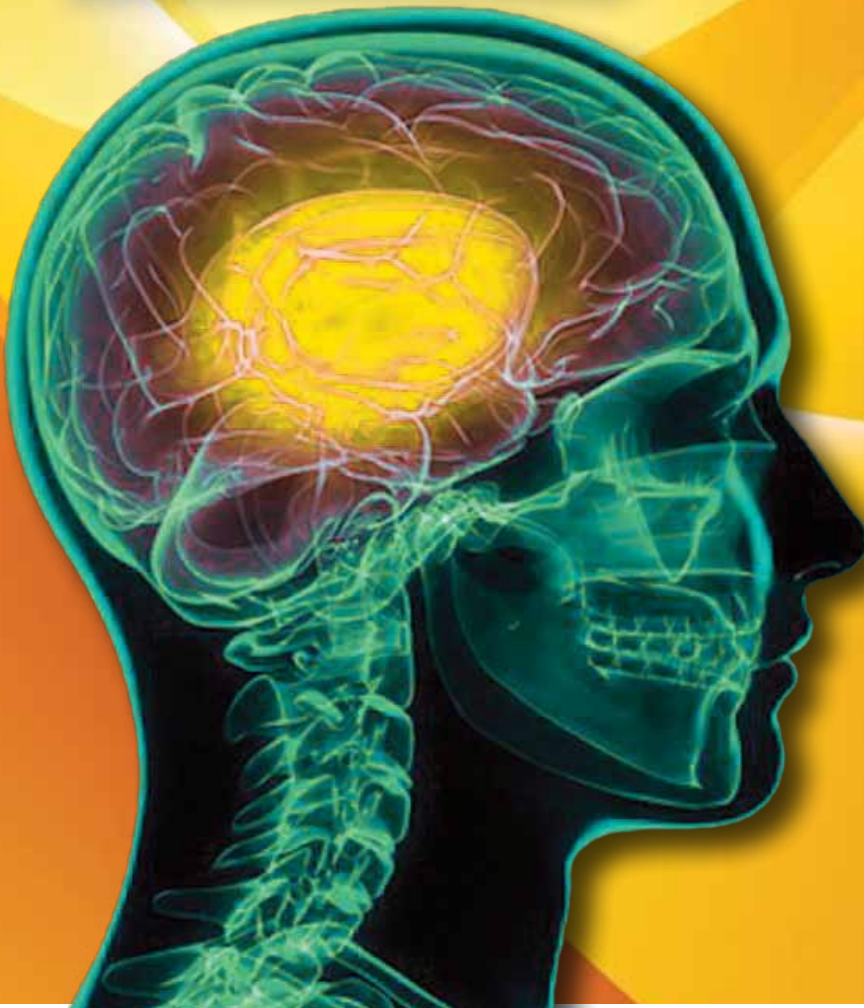THE LAWYER'S LOGBOOK®

For Plaintiff Lawyers Only

Vol. 6, No. 5 2017

BRAIN INJURIES

////// THE MYTHS, THE TESTS AND THE DIAGNOSIS



Three top experts
on the human
brain offer
comprehensive



Dorothy Clay Sims

insight into
measuring and
proving TBI,
Concussions



Dr. Stephanie Stolinsky

and the
misconceptions
about PTSD



Dr. David E. Ross

Endorsed by
APITLAmerica®
Putting the Brakes on
Unsafe Trucking Companies®

NeuroQuant[®] and NeuroGage[®]

Breakthroughs in Objectively Measuring Effects of Mild Traumatic Brain Injury



DAVID E. ROSS, M.D.

Director, Virginia Institute of Neuropsychiatry,
www.VaNeuropsychiatry.org

CEO, NeuroGage LLC, www.NeuroGage.com

Clinical Assistant Professor, Virginia
Commonwealth University

364 Browns Hill Court

Midlothian, VA 23114

DRoss@VaNeuropsychiatry.org

(804) 594-7046

Conflicts or potential conflicts of interest: Dr. Ross is CEO of NeuroGage LLC, maker of NeuroGage[®] software. He is a paid consultant for CorTechs Labs, Inc., maker of NeuroQuant[®] software.

Up until the last few years, it was common for defense physician experts to argue that my patients with chronic mild traumatic brain injury (TBI) had no objective evidence of brain injury. I would argue that objective evidence was not necessary for making a diagnosis of traumatic brain injury. I imagine that it was difficult for the jury members to know who was telling the truth.

Today that situation has dramatically improved. We

now have several objective methods for identifying the effects of mild TBI on the brain. (“Objective” means evidence that cannot be exaggerated or malingered.) The leading methods are MRI brain imaging methods, including: 1) Brain volume measurement; 2) Diffusion tensor imaging (DTI); and 3) Susceptibility-weighted imaging (SWI). I will briefly discuss the latter two before discussing the volumetry techniques in more detail.

SWI currently is the best method for detecting signs of old bleeding (hemosiderin) in the brain. It is better than the older technique of gradient recalled echo (GRE) imaging. SWI is part of our standard MRI protocol. The advantage of SWI is that signs of old bleeding in the brain usually is strong evidence of a previous brain injury, unless there is some other reason the patient had bleeding in her brain. The limitation of SWI is that, in my experience with hundreds of patients, it is positive only about 10-15% of the time in patients with chronic mild TBI.

DTI currently is the most sensitive method for detecting white matter damage. White matter, consisting of the long thin axons, is particularly vulnerable to damage by TBI. Many research studies have shown that DTI is very sensitive to finding evidence of white matter damage in patients with chronic mild TBI. The traditional radiologist’s method of simple visual inspection usually results in the DTI being interpreted as normal. However, in our experience, quantitative DTI (qDTI)—including comparison to a normal control group—detects signs of white matter damage in more than 95% of patients with chronic mild TBI. DTI has been accepted as evidence in many court cases, with no—or almost no—failures to be admitted. Disadvantages of DTI include: 1) There is no FDA-cleared technique for qDTI; 2) To my knowledge, there are only about 5 centers in the country that perform qDTI analyses, and in most cases, the patient will need to be sent to the imaging center that performs the analysis, raising practical challenges; 3) The reliability of DTI between imaging centers generally is unknown; 4) Little is known about longitudinal change with DTI (although that situation has begun to improve recently) and 5) Explaining DTI to a jury can be done, but generally is more challenging than explaining volumetry. For example, it is more difficult to understand “fractional anisotropy” or even “water moving through straws” than “the brain shrunk: sounds bad, is bad.” But overall, DTI is an excellent and promising technique, and we look forward

to its further development particularly with regard to application to individual patients.

In comparison to SWI or DTI, brain volumetry has been around a lot longer. In the 1970s, CT scanning was a major breakthrough in imaging. In the 1980s, MRI scanning came to the forefront as a higher resolution imaging method. By the 1990s, many researchers were measuring brain volume with CT and MRI. However, these techniques involved a human operator tediously drawing regions of interest on the screen, and the method was not practical for clinical settings.

In the late 1990s, this problem was overcome by computer-automated methods like FreeSurfer, which reduced the time needed to measure brain volume from 15 hours to 15 minutes. FreeSurfer was developed at Harvard and Massachusetts General Hospital with over \$100 million of federal funding. FreeSurfer, as the name implies, was free and commonly used by researchers. But it could not be commercially applied because you could not charge patients to use it.

In the early 2000s, NeuroQuant[®] (produced by CorTechs Labs, Inc.) separated from FreeSurfer and was developed as a commercially available product. Since then, the two software programs have evolved separately. In 2006, NeuroQuant[®] became the first FDA-cleared [510(k) K061855] method for measuring MRI brain volume. It is commercially available, computer-automated software which is FDA-cleared to identify and measure brain volume in human subjects. It is not limited to any patient subgroup and can be used essentially in any patient or normal control subject.

NeuroQuant[®] has become the clinical gold standard for measuring MRI brain volume. It is based on thousands of normal control subjects, and produces age- and sex-matched results for subjects ages 3-100 years. It has been used in over 120,000 subjects. As of April 2017, there were

63 peer-reviewed publications using NeuroQuant[®], and the rate of publications has been increasing steadily. Given its community acceptance, reliability and validity, it satisfies the Daubert criteria for admissibility in court (Ross, Graham et al. 2013). Although there have been no Daubert challenges (and therefore no Daubert rulings), NeuroQuant[®] has been admitted as evidence in 3 court cases, with no failures to be admitted: 1) Burrell v. Riverside Hospital, Circuit Court of Newport News (VA), CL1101633F-15 (12/07/12); 2) Federico, et al v. Mid-Atlantic Family Communities, LLC, U.S.D.C. for the Eastern District of Virginia, Norfolk Division, Civil Docket No. 2:12cv80 (04/04/16) and 3) An v. Hekal, Superior Court, Judicial District of Stamford/Norwalk (CT) (04/28/16).

In 2012, NeuroGage[®] was introduced by the Virginia Institute of Neuropsychiatry. (In 2017, the NeuroGage LLC corporation was created and spun off from the Virginia Institute of Neuropsychiatry in order to further the research and development of NeuroGage[®] software for understanding the effects of brain injury or disease on brain volume.) NeuroGage[®] is a software program which is built on NeuroQuant[®] and extends its utility in several important ways, including the following: 1) testing for abnormal asymmetry (Ross, Ochs et al. 2015); 2) longitudinal change over time (Ross, Ochs et al. 2012, Ross, Castelveccchi et al. 2013, Ross, Ochs et al. 2015); and 3) the brain volume estimation method, which estimates brain volume just before injury (Ross, Ochs et al. 2014, Ross, Ochs et al. 2016). NeuroGage[®] analyses have been performed on hundreds of subjects. There 9 peer-reviewed articles supporting its reliability and validity.

Patients with TBI often have abnormal asymmetry, due to the traumatic forces distributed unequally in the brain. The Figure shows an example of a patient with chronic mild

TBI who had abnormal asymmetry in his lateral ventricles and hippocampi. Note that the lateral ventricle enlarged because the adjacent hippocampus atrophied, an example of ex vacuo atrophy. Longitudinal analysis is critically important in mild TBI because the brain volume changes rapidly. Our “Man versus Machine” studies showed that NeuroQuant[®] and NeuroGage[®] were much more sensitive for detecting abnormal volume in chronic mild TBI patients (96% detection rate) than was the radiologists’ traditional technique of simple visual inspection (13% detection rate) (Ross, Ochs et al. 2015). Also we found that patients with chronic mild TBI had progressive brain atrophy, and greater rates of atrophy correlated with decreased ability to return to work (Ross, Ochs et al. 2012, Ross, Castelveccchi et al. 2013, Ross, Ochs et al. 2015).

Our “Back to the Future” study used a novel method of estimating brain volume just before time of injury (based on intracranial volume and age of subject) and found that patients with chronic mild TBI had rapid brain volume changes in the first few months after injury (including atrophy of cerebral white matter, atrophy of gray matter, and enlargement of subcortical nuclei and cerebellum possibly due to neuroinflammation or overactivity), and less rapid changes (although still more rapid than normal) during the first couple years after injury. Based on these results, we now recommend the following times for obtaining brain MRIs after injury: 1) Always obtain the first MRI as soon as possible after injury 2) For patients < 1 year from injury, obtain time 2 MRI two months after time 1 MRI (to look for reduction of inflammation/edema; or progressive atrophy); and 3) For patients > 1 year from injury, obtain time 2 MRI one year after time 1 MRI (to look for chronic progressive atrophy, and to allow time for accumulation of cross-sectional atrophy).

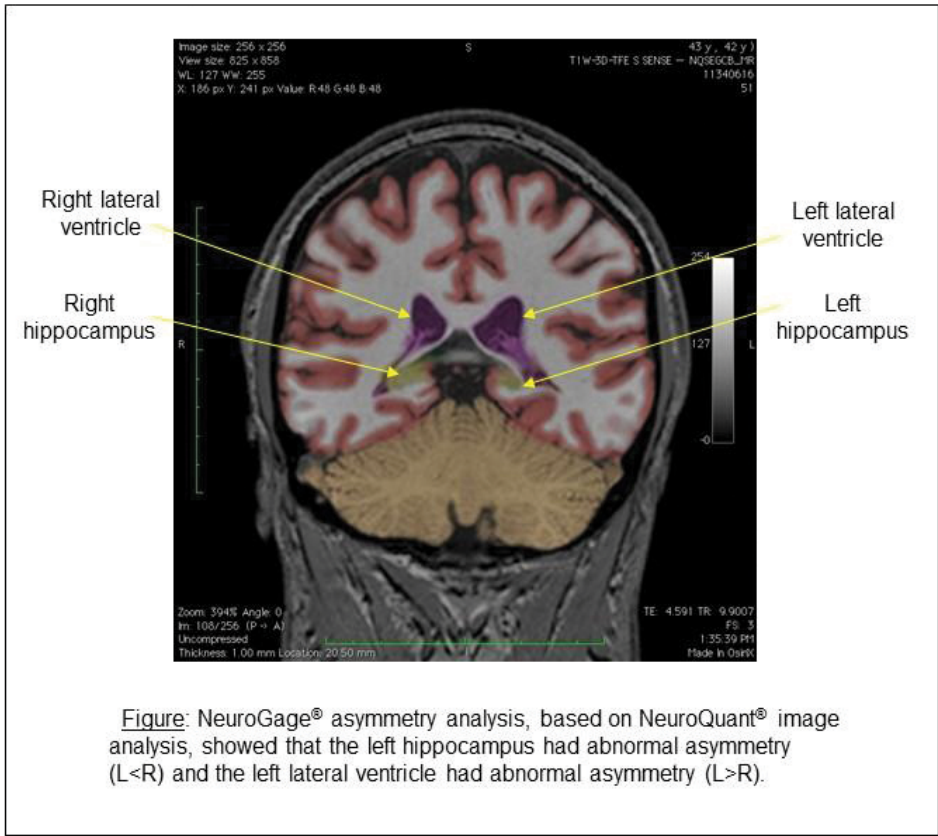


Figure: NeuroGage® asymmetry analysis, based on NeuroQuant® image analysis, showed that the left hippocampus had abnormal asymmetry (L<R) and the left lateral ventricle had abnormal asymmetry (L>R).

volumetry in a single patient with mild traumatic brain injury.” [Brain Injury](#) 27: 634-636.

Ross, D. E., T. J. Graham and A. L. Ochs (2013). “Review of the Evidence Supporting the Medical and Forensic Use of NeuroQuant® in Patients with Traumatic Brain Injury.” [Psychological Injury and the Law](#) 6: 75-80.

Ross, D. E., A. L. Ochs, M. E. DeSmit, J. M. Seabaugh and M. D. Havranek (2015). “Man vs. Machine Part 2: Comparison of radiologists’ interpretations and NeuroQuant® measures of brain asymmetry and progressive atrophy in patients with traumatic brain injury.” [Journal of Neuropsychiatry and Clinical Neurosciences](#) 27: 147-152.

Ross, D. E., A. L. Ochs, J. Seabaugh and T. Henshaw (2012). “NeuroQuant® revealed hippocampal atrophy in a patient with traumatic brain injury.” [Journal of Neuropsychiatry and Clinical Neurosciences](#) 24: E33.

Ross, D. E., A. L. Ochs, J. M. Seabaugh, M. F. DeMark, C. R. Shrader, J. H. Marwitz and M. D. Havranek (2012). “Progressive brain atrophy in patients with chronic neuropsychiatric symptoms after mild traumatic brain injury: A preliminary study.” [Brain Injury](#) 26: 1500-1509.

Ross, D. E., A. L. Ochs, M. D. Zannoni and J. M. Seabaugh (2014). “Back to the future: Estimating pre-injury brain volume in patients with traumatic brain injury.” [NeuroImage](#) 102: 565-578.

Ross, D. E., A. L. Ochs, M. D. Zannoni and J. M. Seabaugh (2016). “Corrigendum to “Back to the Future: Estimating Pre-Injury Brain Volume in Patients with Traumatic Brain Injury” [NeuroImage 102 (Part 2) (15 November 2014) 565–578].” [NeuroImage](#) 127: 510-511.

NeuroGage® has been admitted as evidence in 2 court cases (the Federico and An cases noted above), with no failures to be admitted.

Currently, NeuroQuant® and NeuroGage® include over 80 brain regions. Often anatomic patterns can be detected, for example, correlating enlargement of the third ventricle with diminution of the adjacent thalamus; or correlations with clinical symptoms, for example, atrophy of hippocampus associated with poor short-term memory (Ross, Ochs et al. 2012).

Finally, some practical issues. I recommend using an MRI scanner with a 3.0 Tesla magnet whenever possible, because it results in higher resolution images than a 1.5T scanner. However, 1.5T is good enough to do NeuroQuant® and NeuroGage® analyses. The MRI scan can be done on the vast majority of scanners, which makes the process very convenient. However, the scanner needs to be set up with exactly the correct NeuroQuant® protocol. The NeuroQuant® and NeuroGage®

analyses are done offline, and therefore can be done at any time convenient after the MRI scans. For longitudinal analyses, it is necessary that the patient be scanned on exactly the same scanner at both time points; otherwise inter-scanner differences will be detected and interfere with the results. For NeuroGage® analyses, there are two options: 1) have the imaging center send us the MRI images, and we will perform the NeuroQuant® and NeuroGage® analyses; or 2) for imaging centers that prefer to do their own NeuroQuant® analyses, send us the NeuroQuant® segmented DICOM images (colored brain images), which will allow us to perform the NeuroGage® analyses.

For additional information on NeuroQuant®, see <https://www.cortechslabs.com/neuroquant>. For more information on NeuroGage®, see www.NeuroGage.com.

References

Ross, D. E., C. Castelvechchi and A. L. Ochs (2013). “Brain MRI